

Jacobs Journal of Psychiatry and Behavioral Science

Case Report

A Case of Sneddon's Syndrome Attempted the Suicide Due To Progressive Mental Deterioration

Takashi Kasahara, MD, PhD^{1*}, Kayako Nitta, MD¹, Hidenori Kanke, MD¹, Yuji Koyama, MD, PhD¹, Minoru Toyokura MD, PhD¹

¹Department of Rehabilitation Medicine, Tokai University Oiso Hospital, 21-1 Gakkyo Oiso, Kanagawa, 259-0198, Japan

*Corresponding author: Takashi Kasahara, MD, PhD, Department of Rehabilitation Medicine, Tokai University Oiso Hospital,

Gakkyo 21-1, Oiso, Kanagawa 259-0198, Japan, Tel: +81-463-72-3211; Fax: +81-463-72-2256; E mail: rhkasa@is.icc.u-tokai.ac.jp

Received: 03-20-2016

Accepted: 03-29-2016

Published: 04-03-2016

Copyright: © 2016 Kasahara

Abstract

Sneddon's syndrome (SS) is a rare clinical entity characterized by livedo reticularis (LR) and cerebrovascular disease. This disease is thought to bear some relationship with antiphospholipid syndrome (APS), but the prognosis of SS is more serious than that of APS due to recurrence of cerebral infarction, migraine, and progressive cognitive impairment. We present the case of a 49-year-old woman with diffuse LR of the feet, migraine-type headache, left hemiplegia, and mental deterioration.

Keywords: Sneddon's Syndrome; Livedo Reticularis; Cognitive Impairment; Rehabilitation

Introduction

Sneddon's syndrome (SS) is a rare clinical entity characterized by ischemic cerebrovascular disease such as stroke or transitory ischemic attacks in association with livedo reticularis (LR) [1]. This disease was first described by Sneddon, an English dermatologist, in 1965 [2]. SS is mostly seen in women in early adulthood, with a reported incidence of four cases per million and a mortality rate of 9.5% over a mean observation period of 6.2 years [3]. LR represents the typical cutaneous lesion, and neurological symptoms such as headache, migraine, memory problems, cognitive impairments, dementia, depression, and cerebrovascular disease may also be seen in the course of the disease [4]. The clinical signs of SS reflect pathological changes taking place in the arterioles of the distribution pathway involving the cutaneous-subcutaneous vascular plexuses of the skin as well as the brain and probably other organs (kidney, bowel, eyes) [5]. This disease is thought to have some relationship with antiphospholipid syndrome (APS) and some associations with antiphospholipid antibody [6]. Although exogenous estrogen intake and pregnancy may trigger the appearance of this disease, the pathogenesis has not yet been clarified yet [7]. In this case report, we describe the case of a patient with LR, right retinal artery embolism, and

migraine who experienced left hemiplegia and attempted suicide due to mental deterioration and depression.

Case report

A 49-year-old woman presented to an emergency hospital with symptoms of left-sided weakness, and gait and speech disorders. Past history included cerebral infarction of the right basal ganglia and right middle cerebral artery (MCA) stenosis about 18 years earlier, but no significant sequelae such as paresis or cognitive impairment. Because of the presence of both LR on the feet and cerebral infarction, SS was diagnosed at that time. She was subsequently prescribed prednisolone (PSL) at 5 mg/day and ticlopidine at 100 mg/day by her local medical doctor. No significant family history was identified and she had no history of taking exogenous estrogen or spontaneous abortion.

Laboratory studies showed negative results for antiphospholipid antibodies (anticardiolipin antibodies, lupus anticoagulant), antinuclear antibodies, and anti-double-stranded DNA antibodies. Ischemic changes were apparent in the temporal lobe on cranial magnetic resonance imaging (MRI), matching the perfusion zone of the right middle cerebral artery (MCA), and magnetic resonance angiography revealed occlusion of

the right internal carotid artery and MCA and right-dominant diffuse medium- and small-vessel occlusive disease, with numerous collaterals in the middle and distal circulation, but no evidence of atherosclerosis or vasculitis. Echocardiography and electrocardiography yielded normal results.

After she was prescribed PSL at 30 mg/day and warfarin at 3.5 mg/day, left paresis gradually improved. However, about 1 month after admission, right retinal artery embolism and a larger cerebral infarction occurred in the region of the right MCA and posterior cerebral artery (Fig. 1), resulting in right blindness and severe left paresis. Two months after admission, she was transferred to our hospital for rehabilitation.

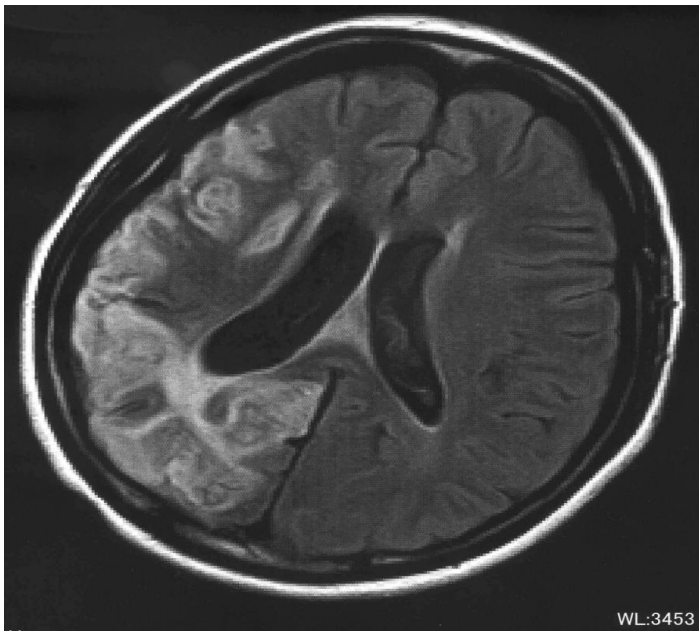


Figure 1. Ischemic changes in the temporal and occipital regions match the perfusion sites of the right middle and posterior cerebral arteries on cranial magnetic resonance imaging.

General examination showed LR involving the lower extremities (Fig. 2) and normal results from pulmonary and cardiac auscultation.

The patient was alert and cooperative for the neurological examination, but responses were slightly slow. She showed mild dysarthria and left facial nerve palsy. Brunnstrom stages for the left upper extremity, hand, and lower extremity were 3, 2, and 4, respectively. Deep tendon reflexes in the upper and lower extremities on the left side were slightly hyperactive, and pathological reflexes were negative. Neurological examinations of the upper and lower extremities on the right side showed no abnormalities. Ranges of motion were also normal for almost all joints.

As for higher brain functions, the score on the Mini-Mental State Examination was 25/30, the Trail-Making Test and Ra-

ven's colored progressive matrices test were impossible, and score for the Behavioral Inattention Test was under the cut-off. The patient refused further detailed testing.

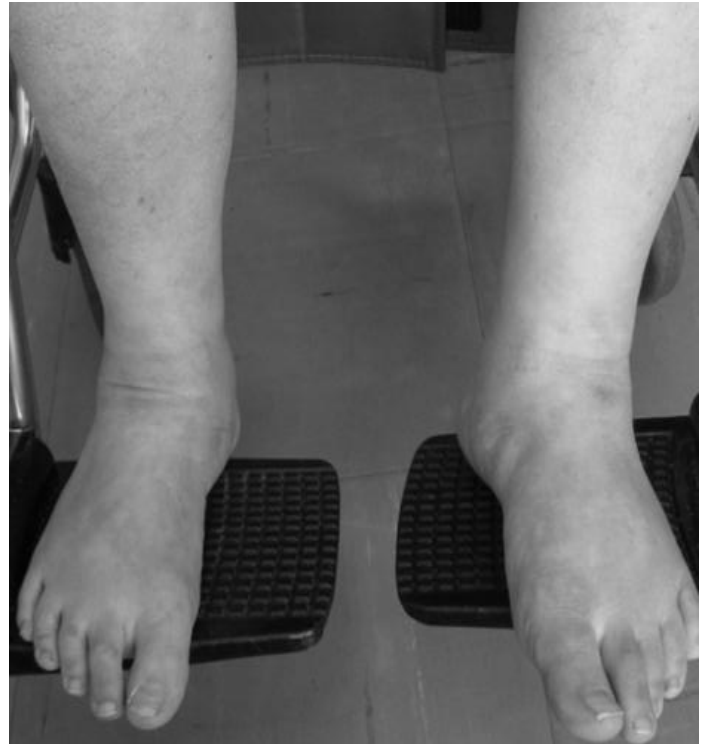

Figure 2. Appearance of livedo reticularis on the patient's feet.

Warfarinization was continued to control the international normalized ratio to within 2.0-2.5, whereas PSL was gradually decreased to 5 mg/month due to hyperglycemia. For the purposes of improving gait disturbance, physical therapy and rehabilitation programs were planned, and a short leg brace was prescribed. However, the patient sometimes refused these interventions due to migraine and general fatigue. At night in the ward, she often shouted out without any apparent reason. Tiapride was administered orally at 75 mg/day to address the excitability of the patient. The patient also teased or spat at therapists during exercise. Although no new discrete stroke-like episodes were clinically apparent, her mental state gradually deteriorated to a child-like state, and she did not want to play the part of a mother or wife. Consequently, the patient was discharged to home in a deeply dependent state in a wheelchair. After discharge, she tried to stab herself with a knife in the kitchen in the middle of the night, but this attempt was interrupted by her mother. Her family members were exhausted by the patient's frequent calls at night, and therefore asked for professional assistance from a caregiver and home rehabilitation service. Unfortunately, however, most services were refused by patient and antipsychotic drugs appeared to have no effect on her mood.

Discussion

APS is the most frequent type of acquired thrombophilia, defined by the occurrence of thrombosis or pregnancy-related morbidity in the presence of persistently positive antiphospholipid antibodies [8]. Conversely, the prevalence of antiphospholipid antibody in SS reportedly ranges from 40% to 50% [9]. Although the relationship between APS and SS is unclear, these antibodies are thought to play important roles in the pathogenesis of SS [3]. Clinical features of APS and SS may overlap, but distinctive clinical and laboratory evidence suggests that these two presentations represent different pathological entities. Several associated coagulopathies have been observed, including elevated levels of coagulation factor VII, decreased levels of protein S, and activated protein C resistance, suggesting a possible biological link between the vasculopathy and a primary coagulopathy in SS [10]. Moreover, the clinical course seems to be progressive in SS patients and includes increasing disability, cognitive deterioration, and advancing arterial involvement [11]. In other words, SS is a disease on the same spectrum as APS, but with a more serious prognosis due to the recurrence of cerebral infarctions and the multitude of complications such as migraine, progressive cognitive impairment, occasional cardiovascular disease, or disturbance of visual acuity. APS shows a more benign course [12]. No effective treatments have yet been identified for SS [6]. Anticoagulation is indicated for SS associated with APS, whereas antiplatelet therapy is the accepted treatment for SS not associated with APS [13]. However, evidence for these treatments is lacking.

SS is a rarely seen disorder, so reports about rehabilitation are scarce. Lalanne et al. reported a case in which the patient attempted suicide in the context of bipolar symptoms leading to a diagnosis of SS [14]. In our case, anticoagulant and antiplatelet therapy could not prevent mental deterioration and antipsychotic drugs failed to improve mental condition. Furthermore, rehabilitative intervention proved ineffective due to progressive mental deterioration, and the patient attempted suicide after discharge. Wright et al. postulated that dementia in SS patients was due to the cumulative effects of multiple cerebral infarcts [4].

To avoid the miserable consequences of this disease, precautions against stroke may be important. Coexistence of LR and neurological symptoms is definitive for SS, but LR and stroke do not appear at the same time, with LR appearing about 5 years earlier than cerebrovascular symptoms [15]. Headaches and dizziness often precede LR by an average of 3.5 years and precede neurological symptoms by an average of 9 years [5]. Neurological symptoms thus need to be monitored very carefully in cases showing LR and migraine. Confirmed trigger factors such as smoking or oral estrogen-containing contraceptives should be avoided and preventive pharmaco-

logical therapy initiated [5,7].

Author disclosures: We do not have any conflicts of interest.

References

1. Aladdin Y, Hamadeh M, Butcher K. The Sneddon syndrome. *Arch Neurol*. 2008, 65: 834-835.
2. Sneddon IB. Cerebro-vasküler lesions and livedo retikularis. *Br J Dermatol*. 1965, 77:180-185.
3. Zelger B, Sepp N, Stockhammer G. Sneddon's syndrome: a long-term follow-up of 21 patients. *Arch Dermatol*. 1993, 129: 437-447.
4. Wright RA, Kokmen E. Gradually progressive dementia without discrete cerebrovascular events in a patient with Sneddon's syndrome. *Mayo Clin Proc*. 1999, 74: 57-61.
5. Wohlrab J, Frances C, Sullivan KE. Strange symptoms in Sneddon's syndrome. *Clin Immunol*. 2006, 119: 13-15.
6. Faustino A, Paiva L, Morgadinho A. Cardiac involvement in antiphospholipid syndrome associated with Sneddon syndrome: A challenging diagnosis. *Rev Port Cardiol*. 2014, 33: 115.e1-115.e7.
7. Akbal A, Kurtaran A, Seluk B. A rarely seen syndrome in rehabilitation of hemiplegia: antiphospholipid antibody-negative Sneddon's syndrome. *Rheumatol Int*. 2010, 1489-1491.
8. Ruiz-Irastoza G, Crowther M, Branch W. Antiphospholipid syndrome. *Lancet*. 2010, 376: 1498-1509.
9. Weinstein S, Piette W. Cutaneous manifestations of antiphospholipid antibody syndrome. *Hematol Oncol Clin North Am*. 2008, 22: 67-77.
10. Sanna G, D'Cruz D, Cuadrado MJ. Cerebral manifestations in the antiphospholipid (Hughes) syndrome. *Rheum Dis N Am*. 2006, 32: 465-490.
11. Dutra LA, Braga-Neto P, Pedrosa JL. Sneddon's syndrome: case report and review of its relationship with antiphospholipid syndrome. *Einstein*. 2012, 10: 230-232.
12. Fentoni V, Grisoli M, Salmaggi A. Clinical and neuroradiological aspects of Sneddon's syndrome and primary antiphospholipid antibody syndrome. A follow up study. *Neurol Sci*. 2000, 21: 157-164.
13. Caldas C, Carvalho J. Primary antiphospholipid syndrome with and without Sneddon's syndrome. *Rheumatol Int*. 2011,

31: 197-200.

14. Lalanne L, Elowe J, Danion J-M. A suicide attempt in a context of bipolar symptoms leading to a diagnosis of Sneddon syndrome. *J Neuropsychiatry Clin Neurosci*. 2013, 25: 11-12.

15. Kitagawa Y. Antiphospholipid antibody syndrome and Sneddon's syndrome. *Prog. Med*. 1997, 17: 3031-3038 (in Japanese).